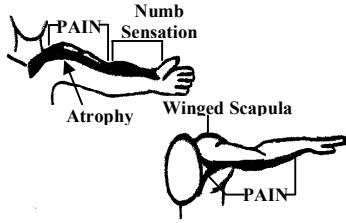


# COMMON SINGLE NERVE ROOT SYNDROMES

## LOWER CERVICAL

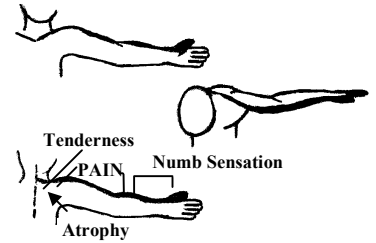
### FIFTH CERVICAL

PAIN upper border scapula  
 TENDERNESS over transverse process C4-5 vertebrae  
 RADIATION of pain to anterolateral arm  
 NUMB sensation anterolateral forearm  
 HYPOALGESIA as outlined, more evident distally  
 REFLEX of Biceps tendon reduced



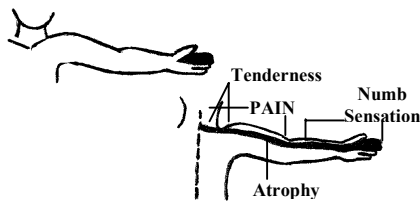
### SIXTH CERVICAL

PAIN upper medial scapula  
 TENDERNESS over transverse process of vertebrae  
 RADIATION of pain to lateral arm  
 NUMB sensation of thumb  
 HYPOALGESIA as outlined  
 REFLEX of Biceps tendon reduced or absent  
 WEAKNESS & ATROPHY of thumb, biceps and scapular muscles.



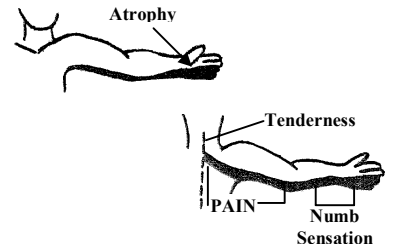
### SEVENTH CERVICAL

PAIN upper border scapula  
 TENDERNESS over transverse process of vertebrae  
 RADIATION of pain to posterolateral arm  
 NUMB sensation 2<sup>nd</sup> & 3<sup>rd</sup> digits  
 HYPOALGESIA as outlined  
 REFLEX of triceps tendon reduced or absent  
 MOTOR WEAKNESS & ATROPHY of triceps muscle



### EIGHTH CERVICAL

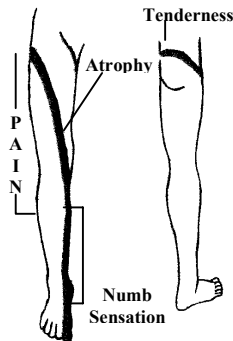
PAIN over medial scapula spine  
 TENDERNESS over transverse process of vertebrae  
 RADIATION of pain to posteromedial arm  
 NUMB sensation 4<sup>th</sup> & 5<sup>th</sup> digits  
 HYPOALGESIA as outlined  
 REFLEX no changes recognized  
 WEAKNESS & ATROPHY of intrinsic muscles of hand.



## LUMBOSACRAL

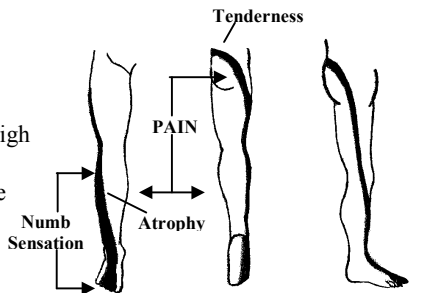
### FOURTH LUMBAR

PAIN in gluteal (hip) region over trochanter  
 TENDERNESS over transverse process of vertebrae  
 RADIATION of pain to anterior thigh & leg  
 NUMB sensation anterior leg, great toe  
 HYPOALGESIA as outlined  
 REFLEX of patellar tendon reduced or absent  
 MOTOR WEAKNESS & ATROPHY of quadriceps muscle



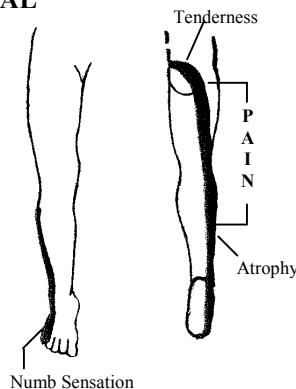
### FIFTH LUMBAR

PAIN in gluteal (hip) region between ischial tuberosity & greater trochanter  
 TENDERNESS over transverse process of vertebrae  
 RADIATION of pain to lateral thigh & leg  
 NUMB sensation lateral leg, three middle (or great) toes  
 HYPOALGESIA as outlined  
 REFLEX usually no alteration  
 WEAKNESS & ATROPHY of dorsal flexors of ankle and toes.



### FIRST SACRAL

PAIN in medial gluteal (hip) region over ischial tuberosity  
 TENDERNESS over transverse process of vertebrae  
 RADIATION of pain to posterior thigh & leg  
 NUMB sensation posterior leg, little toe  
 HYPOALGESIA as outlined  
 REFLEX of Achilles tendon reduced or absent  
 MOTOR WEAKNESS & ATROPHY of plantar



### SECOND SACRAL

PAIN in medial gluteal fold  
 TENDERNESS over upper lateral sacrum  
 RADIATION of pain to posteromedial thigh, leg & heel  
 NUMB sensation medial gluteal fold, labrum major or scrotum.  
 HYPOALGESIA as outlined  
 REFLEX planter flexion; response reduced  
 WEAKNESS & ATROPHY none recognized.

